

Histoplasmosis y bacteremia persistente por *Staphylococcus aureus* meticilino-resistente asociada a derivación ventriculoperitoneal: reporte de caso

Carolina Álvarez-Ortega¹, David E. Rebellon-Sanchez², Juan Camilo Marquez³, Juan Diego Vélez⁴, Natalia Ramos-Ospina⁵, Valeria Zuñiga-Restrepo⁶, Pablo A. Moncada-Vallejo^{7,*}

Resumen

La histoplasmosis es una infección fúngica causada por *Histoplasma ssp.*, que afecta principalmente el sistema respiratorio, mientras que *Staphylococcus aureus* resistente a la meticilina (SARM) es una bacteria notoria por ser resistente a los antibióticos y asociarse con infecciones graves. Presentamos un informe de caso de una mujer de 33 años con antecedente de hidrocefalia que se sometió a la colocación de una derivación ventriculoperitoneal (VP) y posteriormente fue llevada al servicio de urgencias debido a debilidad muscular progresiva y síntomas sugestivos de infección sistémica. Evaluaciones adicionales revelaron paquimeningitis, anomalías pulmonares y diagnósticos de histoplasmosis y bacteriemia por SARM que persistió durante varias semanas a pesar de la terapia antibiótica dirigida. La bacteriemia solo se resolvió después de que se retirara la derivación. Este caso resalta la importancia de considerar diversas etiologías, realizar investigaciones diagnósticas oportunas con un historial médico completo y adoptar enfoques de tratamiento adaptados para casos complejos que involucran infecciones concomitantes.

Palabras clave: Histoplasmosis, *Staphylococcus aureus* resistente a la meticilina, Bacteremia Persistente, Derivación Ventriculoperitoneal, reporte de caso

Histoplasmosis and persistent methicillin-resistant *Staphylococcus aureus* bacteremia associated with a ventriculoperitoneal shunt: a case report

Abstract

Histoplasmosis is a fungal infection caused by *Histoplasma ssp.* that primarily affects the respiratory system, while methicillin-resistant *Staphylococcus aureus* (MRSA) is a notorious antibiotic-resistant bacterium associated with severe infections. We present a case report of a 33-year-old female with history of hydrocephalus that underwent a VP shunt placement and was brought to the emergency department due to progressive muscle weakness and symptoms suggestive of systemic infection. Further evaluations revealed pachymeningitis, lung abnormalities, and diagnoses of histoplasmosis and methicillin-resistant *Staphylococcus aureus* (MRSA) bacteremia, which persisted for several weeks despite targeted antibiotic therapy. The bacteremia only resolved after the shunt was removed. This case underscores the importance of considering diverse etiologies, conducting timely diagnostic investigations with a complete medical history, and adopting tailored treatment approaches for complex cases involving concomitant infections.

Keywords: Histoplasmosis, Methicillin-Resistant *Staphylococcus aureus*, Persistent Infection, Ventriculoperitoneal Shunt, Case reports.

1 Fundación Valle del Lili, Centro de Investigaciones Clínicas, Cali, Colombia. <https://orcid.org/0000-0001-7703-5883>
2 Fundación Valle del Lili, Centro de Investigaciones Clínicas, Cali, Colombia. <https://orcid.org/0000-0002-9680-9108>
3 Fundación Valle del Lili, Departamento de Imágenes diagnósticas, Servicio de Neuroradiología, Cali, Colombia. <https://orcid.org/0000-0001-8135-3518>
4 Fundación Valle del Lili, Departamento de Medicina Interna - Servicio de Enfermedades Infecciosas, Cali, Colombia. <https://orcid.org/0000-0002-7362-0345>
5 Fundación Valle del Lili, Centro de Investigaciones Clínicas, Cali, Colombia. <https://orcid.org/0000-0001-8349-2685>
6 Universidad Icesi, Facultad de Ciencias de la Salud - Medicina Interna, Cali, Colombia. <https://orcid.org/0000-0002-9891-4235>

7 Fundación Valle del Lili, Departamento de Medicina Interna - Servicio de Enfermedades Infecciosas, Cali, Colombia. <https://orcid.org/0000-0001-9170-3016>

* Autor para correspondencia:
Correo electrónico: pablo.moncada@fvl.org.co

Recibido: 04/09/2023; Aceptado: 23/03/2024

Cómo citar este artículo: C. Álvarez-Ortega, et al. Histoplasmosis y Bacteremia Persistente por *Staphylococcus aureus* Meticilino Resistente asociada a Derivación Ventriculoperitoneal: reporte de caso. *Infectio* 2024; 28(2): 130-134
<https://doi.org/10.22354/24223794.1179>

Introduction

Persistent *Staphylococcus aureus* bacteremia (SAB) represents 3% to 6% of all *Staphylococcus aureus* infections, with an associated mortality of about 30%¹. The main risk factors for persistent bacteremia caused by *Staphylococcus aureus* are hospital-acquired infections, methicillin resistance, prior invasive procedures, underlying chronic diseases such as hypertension or diabetes mellitus, the presence of a central venous catheter, and other medical devices²⁻⁴. Additionally, in some cases, *Staphylococcus aureus* can be accompanied by other co-infections, which can increase the risk of complications, adverse outcomes, and multidrug resistance⁵. To our knowledge, there are no documented cases of persistent methicillin-resistant *Staphylococcus aureus* (MRSA) concomitant with disseminated histoplasmosis in immunocompetent patients.

Fungal central nervous system (CNS) infections are uncommon and should be considered emerging pathogens due to the increased number of patients taking immunosuppressive medications, transplant recipients, and worldwide travel⁶. In Latin America, histoplasmosis is a common opportunistic infection among immunocompromised patients with diseases such as HIV/AIDS, with a mortality rate of 20%⁷. In immunocompetent patients, its presentation is infrequent and represents a diagnostic challenge⁸. This case highlights the significance of the prompt diagnosis of two pathologies that have unusual presentations in immunocompetent patients and result in a dismal prognosis.

Case presentation

A 33-year-old female with a six-month history of involuntary weight loss and one-month history of headache, fatigue, malaise, and progressive ascending weakness, along with urinary retention in the last week. She had a history of normal pressure hydrocephalus (NPH), for which she underwent the insertion of a ventriculoperitoneal shunt two years ago. The shunt was replaced one month ago. At an initial care hospital, Guillain-Barré Syndrome was suspected, leading to the administration of intravenous immunoglobulin. Despite the treatment, the patient's weakness persisted and eventually progressed to ventilatory failure. Consequently, she was transferred and admitted to our institution. The patient was presented with orotracheal intubation, bilateral facial palsy, decreased strength in all four limbs, diminished deep tendon reflexes, and preserved sensitivity without meningeal signs. A bladder catheter was inserted due to urinary retention.

The patient was admitted to the Intensive Care Unit (ICU) for management. Various etiologies, including syphilis, tuberculosis, and invasive fungal diseases, oncological and inflammatory diseases such as sarcoidosis and granulomatosis were also considered and ruled out, as well as idiopathic causes. Laboratory studies showed chronic anemia, leukocytosis, and elevated C-reactive protein (Table 1). A contrast-enhanced thoracoabdominal CT scan revealed extensive centrilobular micronodules with diffuse interstitial thickening, and para-aortic adenopathy (Figure 1). A fibro-bronchoscopy with

bronchoalveolar lavage (BAL) was performed. The results were remarkable for a fungal culture positive for *Histoplasma capsulatum* (growth of septate hyaline filamentous fungus after three weeks of incubation), while the rest of the infectious tests were negative (Table 1).

The admission head CT scan revealed right temporal encephalomalacia. Subsequently, a lumbar puncture was performed, indicating an opening pressure of 27 cmH₂O. The cerebrospinal fluid (CSF) analysis showed pleocytosis, primarily consisting of lymphocytes (86%), along with hypoglycorrhachia, hyperproteinorrachia, and the presence of erythrocytes. Although the CSF gram stain did not show bacteria, a few white blood cells were present. The PCR test for tuberculosis was negative.

On the second day of ICU hospitalization, the patient developed a fever. Blood cultures were obtained, which revealed bacteremia caused by MRSA. Broad-spectrum antibiotic therapy with Cefepime and Vancomycin was initiated. Bacilloscopic results were negative. A brain magnetic resonance imaging (MRI) was performed which showed an old putaminal infarction and T2 central hyperintensity of the cervicothoracic spinal cord concerning transverse myelitis. In addition, there was an extensive and diffuse leptomeningeal enhancement in the posterior fossa and in the spine.

A wedge pulmonary biopsy and culture were conducted, with a high suspicion of histoplasmosis or sarcoidosis based on the findings from the thoracoabdominal CT scan. The patho-

Table 1. Laboratory studies

Blood count cells	Values
Hemoglobin	8.7 g/dL
Leukocytes	9870 / μ L
Neutrophils	8.300 / μ L
Linfocytes	460 / μ L
Monocytes	1070 / μ L
Platelets	197000 / μ L
Biochemistry	
Serum creatinine	0.55 mg/dL
Albumin	2.6 g/dL
AST	6.9 U/L
ALT	11.10 U/L
Total bilirrubine	0.34 mg/dL
Infectious markers	
C reactive protein	15.9 mg/dL
HIV antibodies	Negative
HTLV antibodies	Negative
RPR	Negative
Antigen of <i>Cryptococcus</i>	Negative
Autoimmune diagnostic tests	
ANAs	1:80 diils
Anti-DNA	Negative

HIV: Human Immunodeficiency Virus, HTLV: Human T-lymphotropic virus, RPR: Rapid Plasma Reagin, ALT: Alanine aminotransferase, AST: Aspartate aminotransferase, ANA: Antinuclear antibody.

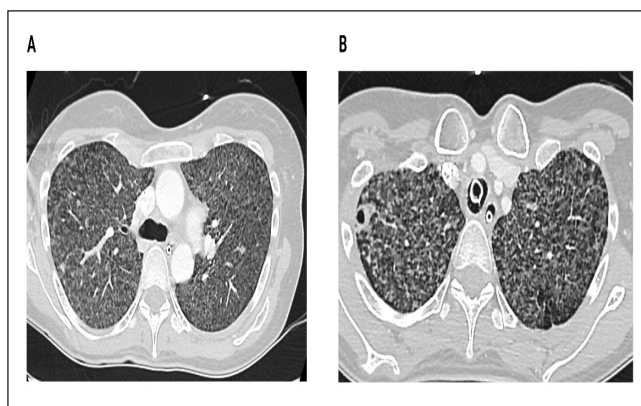


Figure 1. Contrast-Enhanced Chest Computed Tomography. T2 Lung axial view. Centrilobular micronodules with linear branching pattern (Tree-in-bud sign) and multiple heterogeneous spiculated soft-tissue nodules involving both lungs more prominent in the apical regions of both with the presence of a pulmonary cavitation.

logy examination of the lung specimen revealed chronic granulomatous inflammation with focal necrosis and tested positive for MRSA.

The clinical presentation suggested the possibility of tuberculosis or histoplasmosis, although microbiological isolates have not been obtained at this point. Consequently, empirical management was initiated to address both conditions. The anti-tuberculous treatment regimen consists of Rifampicin, Isoniazid, Pyrazinamide, and Ethambutol. Additionally, as adjuvant therapy for meningitis, Liposomal Amphotericin B, Ivermectin (administered in two doses), and IV Dexamethasone were administered.

The *Histoplasma* urine antigen (UAg) was positive (1.4 ng/mL, Normal value = < 0.2 ng/mL). At that time, the patient's diagnosis was disseminated histoplasmosis with MRSA bacteremia.

Subsequently, the therapy was adjusted for the first pathogen with amphotericin B, and Posaconazole was initiated for continued outpatient therapy. For MRSA bacteremia, IV Vancomycin antibiotic was switched to IV Ceftaroline. (Figure 2).

The patient gradually regained strength in all four limbs. The weaning process from invasive mechanical ventilation was initiated two weeks after admission but was unsuccessful, leading to the necessity of a tracheostomy. Finally, after two months of hospitalization, the patient was discharged with homecare support.

However, despite the management, the patient was readmitted to the emergency department fourteen days after discharge due to persistent fever and malaise. The blood cultures revealed positive results for MRSA once again. To further investigate the source of infection, a positron emission tomography-computed tomography (PET-CT) scan was performed, which did not show any clear hypermetabolic foci. As a result, infectious diseases and neurosurgery teams decided to remove the ventriculoperitoneal shunt due to a high suspicion of colonization by MRSA causing persistent bacteremia.

Once the ventriculoperitoneal shunt was removed, resulting in the resolution of bacteremia. Cultures obtained from cerebrospinal fluid yielded negative results for any discernible microorganisms, including MRSA and *Histoplasma*. After approximately three months of hospitalization, the patient was discharged. Posaconazole was prescribed for a duration of six months at a dose of 300 mg every 24 hours (sustained-release tablets). It is noteworthy that the follow-up primarily relied on clinical assessment due to the unavailability of posaconazole levels within our institution. Consequently, the patient's condition improved, and after six months did not require further follow-up.

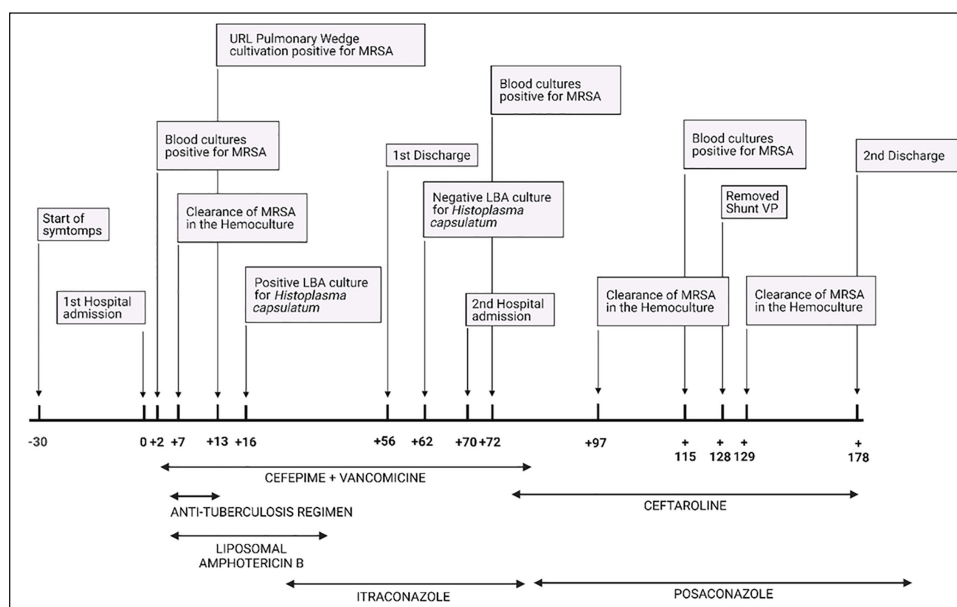


Figure 2: Infections Timeline
 MRSA: Methicillin-Resistant *Staphylococcus aureus*, URL: upper right lobe, VP: Ventriculoperitoneal.

Discussion

In this case, we describe a rare scenario involving the coexistence of histoplasmosis and persistent MRSA bacteremia in a patient with a VP shunt. Histoplasmosis is a fungal infection caused by *Histoplasma ssp.*, primarily affecting the respiratory system, while MRSA is a notorious antibiotic-resistant bacterium associated with severe infections. The combination of these two infections in our patient presented a diagnostic and therapeutic challenge.

The patient was presented with neurologic symptoms and lung opacities. Subsequent analysis of BAL cultures, *Histoplasma* urine antigen (UAg), and blood cultures revealed the presence of both *Histoplasma capsulatum* and MRSA. Notably, neuroimaging demonstrated the rare occurrence of pachymeningitis, a manifestation associated with meningitis caused by histoplasmosis or MRSA^{5,8}. Despite the absence of *Histoplasma* isolation in the cerebrospinal fluid (CSF), the positive *Histoplasma* urinary antigen, combined with its isolation in the bronchoalveolar lavage culture, substantiates the diagnosis of disseminated Histoplasmosis.

The initial diagnostic approach was focused on confirming neuroinfectious diseases, particularly histoplasmosis. This infection is common in the Americas and can cause severe complications in individuals with weakened immune systems. On the other hand, the clinical symptoms in immunocompetent individuals differ based on the size of the infectious particles and the underlying factors⁷. A low level of exposure in healthy hosts usually leads to asymptomatic infection, while acute syndrome typically follows heavy inoculation. The thoracoabdominal CT scan shows diffuse interstitial, reticulonodular infiltrates, associated with hilar and mediastinal lymphadenopathy. Systemic symptoms include fever with respiratory impairment, diaphoresis, weight loss, headache, and gastrointestinal complaints⁵⁻⁷.

The neurological findings, in this case, suggest transverse myelitis, which is a more frequent presentation in viral infections and less common in fungal and bacterial infections^{9,10}. The initial blood cultures were positive for MRSA, which suggested the myelitis to be also due to MRSA. Community-acquired MRSA has increased in frequency, mostly presenting as skin and soft tissue infections. The most frequent invasive forms are osteoarticular and pleuropulmonary, this germ is a rare cause of meningitis^{8,10}. In addition to the neurological and bacteremia findings, the patient's radiological studies revealed lung opacities. The imaging findings suggest a possible infectious process, such as bronchiolitis or pneumonia. Tree-in-bud sign seen on chest x-ray is a common finding in patients with small airway infection, while the multiple nodules with irregular edges and spiculated appearance may suggest malignancy¹². However, given the patient's presentation and medical history, an infectious etiology was more likely.

Initial treatment aimed to eradicate both pathogens and improve the patient's symptoms. Antifungal therapy with itraconazole was unsuccessful due to unavailability of monito-

ring for itraconazole levels at our facility. Additionally, administrative hurdles prevented the timely delivery of the medication from the health insurance provider to the patient. As a result, posaconazole was started on second admission. While itraconazole is traditionally recommended as the primary treatment option, studies have highlighted the effectiveness of newer azoles like posaconazole and voriconazole against *H. capsulatum* in laboratory settings^{13,14}. Posaconazole, specifically, stands out for its activity *in vitro* and successful outcomes in experimental infection models¹³.

Evidence on posaconazole for Histoplasmosis with CNS disease, is scarce. However, there have been studies in animal models with disseminated histoplasmosis and aspergillosis with successful treatment with posaconazole, both as first-line and salvage treatment^{15,16}. Posaconazole is known to have good penetration into the CNS and has been compared in animal models against amphotericin B and itraconazole¹⁵, but there are no head-to-head studies in humans. Subsequently, posaconazole has been used successfully in patients with progressive histoplasmosis with lymphohistiocytosis in patients with HIV¹⁷ and has proven to be effective in previous case reports¹⁸. A survey in 2022 found that when there is CNS involvement, 4% of infectious disease physicians recommend posaconazole, compared to 57% who recommend itraconazole in step-down treatment¹⁹. The 2007 update of histoplasmosis management guidelines by the Infectious Diseases Society of America was based on literature up to June 2006. However, since then, novel treatment options such as posaconazole (approved shortly before the guidelines) and isavuconazole have emerged. Surprisingly, despite the availability of these medications, there has been a notable absence of revisions in clinical practice recommendations. Furthermore, the dearth of new data published on therapy guidance highlights a significant gap in current knowledge regarding treatment approaches^{20,21}.

Despite antibiotic treatment and adequate vancomycin trough levels, the patient continued with persistent MRSA bacteremia, but the site of origin of bacteremia was still unknown. She had a history of normal pressure hydrocephalus and an insertion of a ventriculoperitoneal shunt two years ago. The most common causative organisms isolated from infected shunts are *Staphylococcus epidermidis*, *Staphylococcus aureus*, and gram-negative rods²²⁻²⁴. Therefore, the medical team decided to remove the shunt and with consequence the patient's bacteremia was resolved.

The confirmation of co-infection with Gram-positive bacteria and histoplasmosis presents a therapeutic challenge in selecting an optimal antimicrobial regimen. The utilization of broad-spectrum antibiotics and antifungals, such as Vancomycin, Ceftazidime and Amphotericin B carries the potential for complications including acute renal failure, red man syndrome, hepatic toxicity, and others²⁵. Concurrent administration of these medications may further exacerbate the manifestation of these complications. However, a carefully monitored administration of these medications, considering renal and hepatic function along with other clinical manifestations, was implemented. Additionally, the removal of the infectious foci (device) was performed. This

comprehensive approach successfully minimized the risk of complications and proved to be an optimal strategy for treating this case. Thus, it warrants consideration for similar clinical presentations in the future.

This case highlights the importance of a comprehensive diagnostic approach and collaboration among various specialties in managing complex infections. Considering multiple potential pathogens, including endemic ones in certain regions, is crucial for accurate diagnosis and timely treatment. Early removal of foreign bodies should be considered in cases of persistent bacteremia to improve prognosis. Overall, a multidisciplinary approach, thorough diagnostics, and prompt interventions are key to optimizing patient outcomes in challenging infection cases.

Ethical considerations

This study has been approved by the Institutional Ethical Board review of Fundación Valle del Lili.

Consent for publication. Written informed consent was obtained from the patient for the publication of this case report. A copy of the written consent is available for review by the editor of this journal.

Availability of data and materials. Data sharing is not applicable to this article as no datasets were generated or analyzed during the current study.

Conflicts of interest. The authors declare not to have any interest conflicts.

Funding. Self-funded by the authors.

Acknowledgments. The authors would like to express their gratitude to University Hospital Fundación Valle del Lili for their valuable contributions and support in the completion of this case report.

Authors contributions. All authors contributed, read and approved the submitted version of the manuscript.

References

- Chong YP, Park SJ, Kim HS, Kim ES, Kim MN, Park KH, et al. Persistent *Staphylococcus aureus* Bacteremia. *Medicine* (Baltimore). 2013 Mar;92(2):98–108. DOI: 10.1097/MD.0b013e318289ff1e
- Chang FY, MacDonald BB, Peacock JE, Musher DM, Triplett P, Mylotte JM, et al. A prospective multicenter study of *Staphylococcus aureus* bacteremia: incidence of endocarditis, risk factors for mortality, and clinical impact of methicillin resistance. *Medicine* (Baltimore). 2003 Sep;82(5):322–32. DOI: 10.1097/01.md.0000091185.93122.40
- Yp C, Sj P, Hs K, Es K, Mn K, Kh P, et al. Persistent *Staphylococcus aureus* bacteremia: a prospective analysis of risk factors, outcomes, and microbiologic and genotypic characteristics of isolates. *Medicine* (Baltimore) [Internet]. 2013 Mar [cited 2022 Oct 31];92(2). Available from: <https://pubmed.ncbi.nlm.nih.gov/23429353/>. DOI: 10.1097/MD.0b013e318289ff1e
- Risk Factors for Recurrent *Staphylococcus aureus* Bacteremia | Clinical Infectious Diseases | Oxford Academic [Internet]. [cited 2023 Feb 14]. Available from: <https://academic.oup.com/cid/article/72/11/1891/5860449?login=false>. DOI: <https://doi.org/10.1093/cid/ciaa801>
- Maliniak ML, Stecenko AA, McCarty NA. A longitudinal analysis of chronic MRSA and *Pseudomonas aeruginosa* co-infection in cystic fibrosis: A single-center study. *J Cyst Fibros*. 2016 May 1;15(3):350–6. DOI: 10.1016/j.jcf.2015.10.014
- Jia DT, Thakur K. Fungal Infections of the Central Nervous System. *Semin Neurol*. 2019 Jun;39(3):343–57. DOI: 10.1055/s-0039-1688916
- Wheat LJ, Azar MM, Bahr NC, Spec A, Relich RF, Hage C. Histoplasmosis. *Infect Dis Clin North Am*. 2016 Mar;30(1):207–27. DOI: 10.1016/j.idc.2015.10.009
- Staffolani S, Buonfrate D, Angheben A, Gobbi F, Giorli G, Guerriero M, et al. Acute histoplasmosis in immunocompetent travelers: a systematic review of literature. *BMC Infect Dis*. 2018 Dec 18;18(1):673. DOI: 10.1186/s12879-018-3476-z
- Mehmood MA, Patel M, Sanekommu H. Methicillin-Resistant *Staphylococcus Aureus*: A Very Rare Cause of Meningitis. *Cureus* [Internet]. 2020 Sep [cited 2023 Mar 16];12(9). Available from: <https://www.ncbi.nlm.nih.gov/pmc/articles/PMC7550032/>. DOI: 10.7759/cureus.10370
- Beh SC, Greenberg BM, Frohman T, Frohman EM. Transverse Myelitis. *Neurol Clin*. 2013 Feb;31(1):79–138. DOI: 10.1016/j.ncl.2012.09.008
- Abrantes FF, Moraes MPM de, Rezende Filho FM, Pedrosa JL, Barsottini OGP. A clinical approach to hypertrophic pachymeningitis. *Arq Neuropsiquiatr*. 2020 Dec;78(12):797–804. DOI: 10.1590/0004-282X20200073
- Eisenhuber E. The Tree-in-Bud Sign. *Radiology*. 2002 Mar;222(3):771–2. DOI: 10.1148/radiol.2223991980j
- Connolly, P., Wheat, L. J., Schnizlein-Bick, C., Durkin, M., Kohler, S., Smedema, M., ... Loebenberg, D. (2000). Comparison of a New Triazole, Posaconazole, with Itraconazole and Amphotericin B for Treatment of Histoplasmosis following Pulmonary Challenge in Immunocompromised Mice. *Antimicrobial Agents and Chemotherapy*, 44(10), 2604–2608. DOI: 10.1128/AAC.44.10.2604-2608.2000
- Wheat, L. J. (2006). Activity of newer triazoles against *Histoplasma capsulatum* from patients with AIDS who failed fluconazole. *Journal of Antimicrobial Chemotherapy*, 57(6), 1235–1239. doi: 10.1093/jac/dkl1133
- Imai, J. K., Singh, G., Clemons, K. V., & Stevens, D. A. (2004). Efficacy of Posaconazole in a Murine Model of Central Nervous System Aspergillosis. *Antimicrobial Agents and Chemotherapy*, 48(10), 4063–4066. DOI: 10.1128/AAC.48.10.4063-4066.2004
- Restrepo, A., Tobón, A., Clark, B., Graham, D. R., Corcoran, G., Bradsher, R. W., Goldman, M., Pankey, G., Moore, T., Negroni, R., & Graybill, J. R. (2007). Salvage treatment of histoplasmosis with posaconazole. *The Journal of Infection*, 54(4), 319–327. <https://doi.org/10.1016/j.jinf.2006.05.006>
- Schulze, A. B., Heptner, B., Kessler, T., Baumgarten, B., Stoica, V., Mohr, M., ... Berdel, W. E. (2017). Progressive histoplasmosis with hemophagocytic lymphohistiocytosis and epithelioid cell granulomatosis: A case report and review of the literature. *European Journal of Haematology*, 99(1), 91–100. DOI: 10.1111/ejh.12886
- Clark, B., Foster, R., Tunbridge, A., & Green, S. (2005). A case of disseminated histoplasmosis successfully treated with the investigational drug posaconazole. *Journal of Infection*, 51(3), e177–e180. DOI: 10.1016/j.jinf.2005.01.001
- Mazi, P. B., Arnold, S. R., Baddley, J. W., Bahr, N. C., Beekmann, S. E., McCarty, T. P., Polgreen, P. M., Rauseo, A. M., & Spec, A. (2022). Management of Histoplasmosis by Infectious Disease Physicians. *Open forum infectious diseases*, 9(7), ofac313. <https://doi.org/10.1093/ofid/ofac313>
- Wheat, L. J., Freifeld, A. G., Kleiman, M. B., Baddley, J. W., McKinsey, D. S., Loyd, J. E., & Kauffman, C. A. (2007). Clinical Practice Guidelines for the Management of Patients with Histoplasmosis: 2007 Update by the Infectious Diseases Society of America. *Clinical Infectious Diseases*, 45(7), 807–825. doi: 10.1086/521259
- Bobbili, K., Akram, S., Sundareshan, V., Prakash, V., Tyagi, I., Waqar, S., ... Koirala, J. (2016). Comparison of Posaconazole and Itraconazole for treatment of Histoplasmosis. *Open Forum Infectious Diseases*, 3(suppl_1), 1646. doi: 10.1093/ofid/ofw172.1346
- Mcclinton D, Carraccio C, Englander R. Predictors of ventriculoperitoneal shunt pathology. *Pediatr Infect Dis J*. 2001 Jun;20(6):593. DOI: 10.1097/00006454-200106000-00009
- Stevens NT, Greene CM, O’Gara JP, Bayston R, Sattar MTA, Farrell M, et al. Ventriculoperitoneal shunt-related infections caused by *Staphylococcus epidermidis*: pathogenesis and implications for treatment. *Br J Neurosurg*. 2012 Dec 1;26(6):792–7. DOI: 10.3109/02688697.2011.651514
- Paff M, Alexandru-Abrams D, Muhonen M, Loudon W. Ventriculoperitoneal shunt complications: A review. *Interdiscip Neurosurg*. 2018 Sep 1;13:66–70. DOI: <https://doi.org/10.1016/j.inat.2018.04.004>
- Mohsen S, Dickinson JA, Somayaji R. Update on the adverse effects of antimicrobial therapies in community practice. *Can Fam Physician*. 2020 Sep;66(9):651–9. PMID: 32933978