

Scorpion envenomation in Brazil: an update

Arthur Fernandes Barbosa Parrela¹, Raquel Roque Rodrigues¹, Gustavo de Paula Campos¹, Ana Clara Miranda Gomes¹, Bruna Soares de S. Lima Rodrigues¹, Marcella N. Melo Braga², Ademir N. Ribeiro Júnior¹, Rodrigo Siqueira-Batista^{3,*}

Abstract

Accidents caused by scorpions represent a major health problem on planet, both in individual terms and in the public health sphere. Morbid events can occur in different manifestations, and different clinical conditions must be differentiated for adequate treatment. In addition to the potential injury to human hosts, scorpion venom has been investigated for the therapy of several illnesses. Based on these aspects, the present article aims to present the clinical, diagnostic, therapeutic and prophylactic aspects of scorpionism.

Keywords: Scorpions; Scorpion Stings; Scorpion Venoms.

Escorpionismo en Brasil: Una actualización

Resumen

Los accidentes causados por escorpiones representan un problema mayor de salud pública tanto en términos de daños individuales como en la esfera de la salud pública. Los eventos mórbidos pueden ocurrir con diferentes manifestaciones y condiciones clínicas que deben ser diferenciadas para un manejo adecuado. Además del daño potencial que ocasionan a los humanos, el veneno del escorpión ha sido estudiado con el fin de analizar su potencia aplicación para le tratamiento de algunas enfermedades. Este artículo presenta una actualización sobre los aspectos clínicos, terapéuticos y profilácticos del escorpionismo.

Palabras claves: Escorpionismo; Brasil; toxinas

Introduction

Scorpionism – a generic name given to accidents with scorpions – occurs commonly in tropical and subtropical regions (Abroug et al., 2020), representing a serious public health problem, due to its high incidence and clinical relevance. Worldwide, it is estimated that in 2019 there were around 1.2 million accidents and 3500 deaths annually (SBMT, 2019). In Brazil, between 2007 and 2018, approximately 927 thousand cases of entanglement by scorpions were reported, resulting in 972 deaths (Brasil, 2019; Furtado et al., 2020).

The main genus of scorpion found in Brazil is *Tityus*. *Tityus serrulatus* (yellow scorpion) the most prone to the production of serious accidents and with potential evolution to death in country (Brazil, 2009). Such scorpions are investigated – for example, in research units, such as the Butantan Institute –

with the aim to produce serum to neutralize the action of the venom and to investigate the eviction reactions in human organism (Batista, 2016). In about 95% of cases, involvement is restricted to the location where the bite occurs. However, potentially serious accidents can occur, especially at extremes ages (infants and the elderly) and in those situations in which there is a delay between entanglement and access to hospital care (Abroug et al., 2020; Carmo et al., 2019). Despite the lesions produced by scorpionic toxins, such components have been studied – with promising results – for the treatment of morbid conditions in human medicine.

Considering these brief notes, the present article aims to present the main clinical characteristics of scorpionism, also emphasizing the diagnosis, differential diagnoses, treatment and prevention of this condition.

1 Escola de Medicina da Faculdade Dinâmica do Vale do Piranga.
2 Departamento de Bioquímica e Imunologia, Universidade Federal de Minas Gerais.
3 Departamento de Medicina e Enfermagem da Universidade Federal de Viçosa e Escola de Medicina da Faculdade Dinâmica do Vale do Piranga.
* Autor para correspondencia:
Correo electrónico: Imecs@ufv.br
Universidade Federal de Vicosa - Medicina e Enfermagem Avenida Peter Henry Rolfs, s/n 0 Viçosa Vicosa MG 36570-900 Brazil

Recibido: 31/01/2021; Aceptado: 21/08/2021

Cómo citar este artículo: A. Fernandes Barbosa Parrela, et al. Scorpion envenomation in Brazil: an update. Infectio 2022; 26(2): 172-180

Scorpions in Brazil

In Brazil there are four scorpion families: *Buthidae*, *Bothriuridae*, *Chactidae* e *Hormuridae* (Bravo & Calor, 2014). The *Tityus* genus, belonging to the *Buthidae* family, presents the biggest species number in the country, totaling fifty-four. Among these species, it is possible to highlight the main responsible for serious accidents in Brazil, such as, *Tityus serrulatus*, *Tityus bahiensis*, *Tityus stigmurus*, *Tityus paraensis* and *Tityus silvestris* (Figure 1 and Figure 2) (Reckziegel, 2013; Kuiava, et al., 2019).

Tityus serrulatus (Figure 1A) species is popularly known as yellow scorpion due to the yellow color of its legs, pedipalp and metasome. It is approximately 7 cm long, dark brown in color on the back of the prosome and the metasome, and dorsal serration on the 3rd and 4th segments of the metasome, the latter being more robust in the male than in the female. This species' reproduction is paternogenetic, with the female being able to reproduce about 160 offspring throughout her life. This is the species that causes the largest number of serious accidents and deaths in the country. Due to its high and rapid proliferation – and good adaptation to urban environments – it is usually found in the Northeast, Midwest, Southeast and South regions (Brazil & Porto, 2010).

Tityus bahiensis (Figure 1B) – also known as brown or black scorpion – is about 7 cm long, has brown legs and pedipalps, dark metasoma and back of the prossoma and mesosome, legs and pedipalps with dark spots. The male's pedipalp of the tibia is larger than female's. Unlike *T. serrulatus*, this spe-

cies has no serrations in the metasome (Puerto, et al., 2017). It represents the second biggest cause of serious accidents in Southeast Region, mainly among children. It is possible to find it, equally, in the Midwest and South (Dias, 2016).

Tityus stigmurus (Figure 1C) is known as a yellow scorpion from the Northeast, it is about 7 cm long, yellow legs, pedipalp and metasome, and, unlike, *T. serrulatus*, has a longitudinal band, dark on the back of the mesosome, with two smaller bands on the sides, followed by a triangular spot on the back of the prossoma (Puerto et al., 2017). In addition, this species has a dorsal serration in the 3rd and 4th follow-up of the metasome and reproduction is paternogenetic, male has a thinner pedipalp and greater metasome than the female. It can be found in the Southeast and Northeast regions, responsible for the highest number of accidents (Silva et al., 2016).

Tityus paraensis (*syn. Tityus obscurus*) (Figure 1D), popularly known as black scorpion from the Amazon, is black in adulthood and is about 9 cm long. In young phase, it has appendages and brown body, stained with dark, which can be confused with other species of Amazonian scorpions. It is found in the Midwest and North regions, causing many accidents mainly in Pará and Amapá (Brazil & Porto, 2010).

Tityus silvestris is between 2.5 and 4.5 cm long and has a yellowish-brown color with spots on the body, legs and palps, except for the last segment of the tail and telson. In addition, it has a thorn under the stinger. This species can be found in the Midwest and North regions, especially in Pará and Amazonas (Coelho et al., 2016).




Figure 1. Species of scorpions of medical importance in Brazil: A – *Tityus serrulatus*; B – *Tityus bahiensis*; C – *Tityus stigmurus*; and D – *Tityus paraensis* (*syn. Tityus obscurus*). Prepared by Ademir Nunes Ribeiro Júnior.

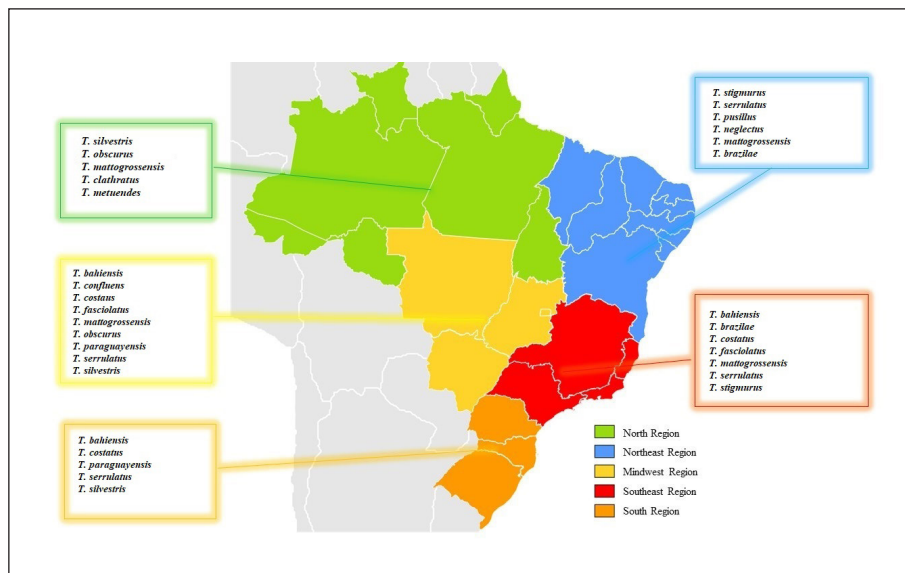


Figure 2. Distribution of the main species of the genus *Tityus*, in Brazil. Prepared by Ana Clara Miranda Gomes. Sources: Brazil e Porto (2010); Carvalho et al. (2017); Lira et al. (2021); Lourenço (2002).

Biochemistry of venom and scorpionism pathogenesis

It is estimated that there are about 100,000 components in the scorpion venom; however, only a small part of its biochemical diversity is known (Triches, 2017). The constitution of the venom depends on the species, life habits and the geographic distribution of the animals. The venom – usually separated into two parts, a water-soluble and a water-insoluble – is produced in the pair of glands located in the telson. Only the soluble part is considered toxic, containing in addition to neurotoxic proteins, lipids, enzymes, nucleosides, nucleotides, free amino acids, peptides and carbohydrates. The insoluble portion, on the other hand, is non-toxic, and is composed of mucoproteins and membrane debris (Reckziegel & Pinto, 2014; Nencioni et al., 2018; Galvani, 2019).

The production and storage of the scorpion venom are associated processes with considerable energy expenditure, so that the amount of venom inoculated can be manipulated by the arthropod, according to the threat level (Abroug et al., 2020; Ismail & Abd-Elsalam, 1988). This fact probably explains the mild clinical manifestations in 95% of victims stung by scorpions (Abroug et al., 1999; Abroug et al., 2020).

The venom, after being inoculated in a victim, stimulates the sodium channel receptors in nonspecific nerve endings, causing cell membrane depolarization and intense release of catecholamines and acetylcholine, which act in different parts of the body and, consequently, generate the majority of clinical manifestations (Weiss, 2018).

The main manifestation is local pain, which can vary in intensity and is characterized by a burning or a prickling sensation. Hyperemia, scarification, pruritus, hyperesthesia, paraesthesia, edema, sweating and piloerection are also described (Abour-

zak et al., 2009; França et al., 2015; Reis et al., 2019). Some of the clinical findings are the result of the type IV hypersensitivity reaction, evidencing the influence of the immune system on the development of local symptoms (Reis et al., 2019). One can also mention the action of hyaluronidases and metallo-proteinases, which degrade the extracellular matrix of the skin, and vasoactive amines that favor increased blood flow to the affected region, intensifying hyperemia and edema (Abourazak et al., 2009; Reis et al., 2019; Machado, 2016; Pucca et al., 2015; Rahmani & Jalali, 2012).

To analyse scorpion's venom, it can be extracted from the telson, through maceration in saline solution or by electric shock. This last method allows the animal to stay alive and only the venom is obtained, unlike maceration. Initially, toxins from the venom were studied in order to find antidotes for accidents caused by these venomous animals. Subsequently, it was observed that the poison could be used as a medicine, which is still under investigation, as will be seen in part 2 of this manuscript (Hassan, 1984; Oguiura, 2004; Bernardes-Oliveira, 2019).

The components of scorpion venom can be classified into two distinct groups of peptides: (1) those that have a disulfide bridge in their molecular structure – the bridge-disulfide peptides (PPD) – and (2) those that do not have disulfide bridges in their structure – non-bridge-disulfide peptides (PNPD) (Almaaytah & Albalas, 2014; Furtado et al., 2020). PNPDs are known for their antimicrobial activity, for being bradykinin enhancers, and for modulating the immune response (Almaaytah & Albalas, 2014; Furtado et al., 2020; Zhi-jian et al., 2006). PPDs, in turn, are toxic components that act on ion channels, inducing the release of neurotransmitters, cholinergics and adrenergics, which explain the rela-

ted symptoms; with sympathetic and / or parasympathetic effects. In addition, the peptides in this group are intrinsically associated with the induction of the inflammatory response (Pucca et al., 2015; Reis et al., 2019).

The main studies about the scorpion venom come from research on species that cause serious accidents, such as *T. serrulatus* and *T. bahiensis* (Lourenço & Eickstedt, 2009). The poison that is most investigated is the one of the species *T. serrulatus*, which some substances are already isolated and recognized.

The neurotoxins Ts1 (TsTX-1 or γ toxin), Ts2 (TsTXIII or III-8), Ts3 (TsTX or *Tityustoxin*) and Ts5 (TsTX-V) act by binding to the post-ganglionic sodium ion channels, causing depolarization of membranes by Na⁺ influx. The toxins Ts6 (TsTXIV), Ts7 (TsTX-K α or TsII-9), Ts8 (TsTX-K β or TsK2), Ts9 (Ts κ), Ts15 and Ts16 act in the post ganglionic potassium ion channels blocking the influx of K⁺ for the cell, concentrating in the extracellular medium. Therefore, the toxins Ts1, Ts2, Ts3 and Ts5 act in synergy with the neurotoxins Ts6, Ts7, Ts8, Ts9, Ts15 and Ts16 (Brites-Neto, 2019). The Ts4 peptide, also called TsTX-VI, causes hypersensitivity reaction, tearing and dose-dependent release of glutamate and GABA. The T peptide (Ts10) intensifies the activity of bradykinin, that is, the toxin inhibits the angiotensin-converting enzyme (ACE) that hydrolyzes bradykinin and prevents the conversion of angiotensin I to angiotensin II, in addition to inhibiting tissue kinase II. Despite not inhibiting ACE, hypotensins 1, 2, 3 and 4 accentuate the hypotensive action of bradykinin and, consequently, cause vasodilation (Brites-Neto, 2019).

Typically, the toxicokinetics of the compounds present in the venom are described as rapid absorption and blood distribution, high tissue affinity and slow excretion. In young people, absorption and distribution are faster and elimination is slower than in older people. Thus, toxicokinetics depends on the individual's age group, with symptoms worsening in young and old (Soto-Blanco & Melo, 2018).

Through the activation of Na⁺ channels, the neurotoxin Ts1 is capable of causing the depolarization of cell membranes and the release of catecholamines (adrenaline and norepinephrine) and acetylcholine. Catecholamines mainly cause adrenergic effects by stimulating the sympathetic nervous system and acetylcholine stimulates the parasympathetic causing cholinergic symptoms. Catecholamines cause an increase in systemic blood pressure, constriction of peripheral vessels, cardiac arrhythmias and, occasionally, acute pulmonary edema, heart failure and shock (Siqueira-Batista et al., 2004). Acetylcholine causes an increase in some secretions, such as nasal, lacrimal, salivary, bronchial, gastric and sweat, in addition to muscle spasms, trembles and decreased heart rate (Paz, 2020).

In addition to the neurotransmitters' release, some venom toxins can directly stimulate sensitive nerves through sodium ion channels, releasing neuropeptides – similar to substance P – which sensitize other nerve fibers distant from the ino-

ulation region and activate NK1 tachykinin receptors. This activation causes contraction of the intestinal smooth muscle and inflammation. This occurs due to the activation of NK1 receptors in mast cells, which stimulate the release of inflammatory components, such as platelet activating factor (PAF), interleukins (IL-1, IL-2, IL-6 and IL-10) and leukotrienes. These components can cause pulmonary edema, due to increased pulmonary capillary permeability, and hemodynamic dysfunctions, due to the increase in systemic blood pressure (Soto-Blanco & Melo, 2018).

Clinical aspects

The large number of scorpion accidents and the variety of existing species shows the importance of describing the signs and symptoms of the affected patients. Thus, mild forms up to severe pictures of scorpionism are reported. As the first symptom after the bite is local pain, markedly described among patients with immediate onset and varying its' intensity. The pain can be irradiated and accompanied by local or limb paresthesias, erythema, piloerection and sweating. It is the main complaint that motivates the search for medical assistance, being described by the patient as burning, needles and / or throbbing (Brasil, 2009; Brasil, 2019).

Around two to three hours on average, the venom may cause systemic manifestations due to the sympathetic and parasympathetic excitation (Siqueira-Batista et al., 2004; Brasil, 2019). Manifestations such as hypo or hyperthermia and deep sweating appear. Disorders of the gastrointestinal tract – such as nausea and vomiting, sialorrhea, abdominal pain and diarrhea – usually come up, and in severe cases, there are reports of acute pancreatitis in patients hospitalized for accidents with scorpions. Cardiovascular alterations are also described, such as bradycardia or tachycardia, hypotension or systemic arterial hypertension, arrhythmias and congestive heart failure, which can cause acute pulmonary edema (enlargement of the cardiac area). Respiratory manifestations – such as tachydyspnea – can be aggravated by the occurrence of acute lung edema. In addition, neurological findings can be expressed with great variety – depending on the toxicity of the venom and the affected sites –, with psychomotor agitation, drowsiness, mental confusion, hypertonia, tremors, miosis, mydriasis, priapism, muscle spasms, systemic paresthesia and ataxia (Funasa, 2001; Albuquerque et al., 2018).

Due to the severe signs and symptoms, there are reports of death from the scorpion accident, the most common cause of which is respiratory failure associated with circulatory shock, aggravated by dehydration and changes in hydroelectrolytic balance (usually related to exacerbated vomiting). In addition to the age, weight and health status of the patient – for example, the presence of pre-existing chronic diseases – medical analysis of the bite's location and the patient's global status is extremely important (Amaral et al., 1991; 1993; Baldini et al., 2010; Elatrous et al., 1999; Geron et al., 1993; Hering et al., 1993; Karnad, 1998).

Diagnosis and laboratorial analysis

In scorpion accidents, the diagnosis must be established on clinical and epidemiological bases. The anamnesis must be detailed and the physical examination meticulous. It is important that the venomous animal, if possible, be captured and taken to the hospital, which may help to conduct the treatment (Brasil, 2001; Brasil, 2019).

There are tests that can be performed for the purpose of complementing the diagnosis and monitoring the clinical evolution and the appearance of complications, including biochemical tests, electrocardiogram, echocardiogram and chest radiography (Brasil, 2010; Brasil, 2019).

In moderate to severe cases, some changes in biochemical tests usually occur, with frequently high blood glucose, hypokalemia and hyponatremia, high amylase, hemolysis and thrombocytosis, leukocytosis with a predominance of neutrophils and an increase in creatinokinase and its MB fraction. Troponin I can be harvested to see if there was damage to the heart muscle (Brazil, 2019).

Changes in the electrocardiogram commonly occur in accidents with *T. serrulatus* and can disappear within three to seven days. The most common events are ventricular extrasystoles, sinus tachy / bradycardia, protruding U waves, atrial fibrillation and T wave inversion in several leads (Brasil, 2019). Like acute myocardial infarction, scorpionism can also show ST-sequence elevation / depression (Brasil, 2016). The echocardiogram is a method used to diagnose myocarditis in cases of scorpionism. The changes vary according to the degree of cardiac dysfunction, which depends on the severity of the case. The most commonly found echocardiographic changes are reduced ejection fraction, global left ventricular hypokinesia and mitral regurgitation (Campos et al., 2020).

A diffuse and alveolar interstitial pattern, expansion of the cardiac area and unilateral costophrenic sinus veiling, showing evidence of acute lung edema can be seen on chest radiography (Martins et al., 2018; Brazil, 2001).

Differential diagnosis

When there is no collection / identification of the stinging scorpion, it is necessary to establish a differential diagnosis as there are several clinical conditions in different diseases that present similar manifestations to scorpionism. Although there are studies that aimed to develop diagnostics by immunoassays to detect components of the venom in patient samples (Rezende et al., 1995; Chávez-Olórtegui et al., 1994; Martins et al. 2018), there is still no method available commercially. Thus, a different diagnosis based on the signs and symptoms of different diseases is essential.

Accidents by other venomous animals are important to offer differential diagnoses. Poisoning by *Lonomia obliqua* differs from scorpion in that it has a burning sensation at the contact site, in addition to promoting hemorrhagic disorders,

such as hematuria, intense bruising, epistaxis, among others (Silva, 2007; Franco et al., 2020). When the suspect is a centipede accident, it is necessary to assess the heart and respiratory rate, since, in these morbid events, these parameters are within the expected, physiologically, different from what occurs in the scorpionic accident (Graça et al., 2008). In the case of an accident by *Micrurus* (true coral), the characteristic that can help differentiate an accident by scorpion is paresthesia, and in the elapidic accident paralysis of different muscle groups can occur, which can even compromise the mechanics ventilation (Brasil, 2001; Siqueira-Batista et al., 2020).

Araneism – that is, accidents by spiders – must be taken into account, since these animals are spontaneously found inside or around houses. Among all spider species, the most important for human medicine are *Phoneutria* ("armadeira spider"), *Latrodectus* (black widow) and *Loxosceles* (brown spider) (Santana et al., 2020a). The wound caused by some of these spiders can be differentiated from the injuries caused by scorpions, since the *Loxosceles* sting has a central bubble that usually evolves into necrosis (Santana et al., 2020b, Barish & Arnold, 2018). When it comes to *Phoneutria* bites, local symptoms are often similar to those of scorpion accidents and are sometimes indistinguishable (Salvatierra et al., 2018; Santana et al., 2020a; Santana et al., 2020b). The crotalic accident (rattlesnake) does not present pain at the site of the bite (when present, the pain is considered mild), in addition to progressing with minor edema and, eventually, systemic disorders, such as sagging facial muscles, ophthalmoplegia, dysgeusia, dysphagia, among others (Brasil, 2001; Siqueira-Batista et al., 2020).

In botulism, for example, there are similar manifestations to those of the scorpion accident; however, one of the outstanding characteristics of botulism is the preservation of conscience, differing from accidents by scorpions, which tend to cause confusion (Brasil, 2006; Gomes et al., 2008). Myasthenia gravis can also be considered a differential diagnosis; however, the patient becomes asthenic with routine and repetitive activities, in addition to reporting a worsening at the end of the day / night, and improves with stillness; in addition, another difference between these two diseases is due to the time of evolution, since myasthenia gravis progresses with a subacute / chronic evolution, different from injuries by scorpions (Branco, 2011; Bizarro et al., 2017).

Insect bites produce – eventually – similar manifestations to those described in scorpion breeding, but, except in severe allergic reactions, those pictures do not usually evolve with systemic involvement (Barish & Arnold, 2018). Dystonic reactions, induced by medication, present as alterations involuntary muscle contractions and repetitive movements of sprain; the history of drug ingestion can help differentiation (Barreira & Magaldi, 2009).

Another disease that must be taken into account is tetanus. However, this condition presents a few symptoms like muscle hypertonia, trismus, in addition to contractures and pain

in the back and limbs (Brasil, 2019). Acute pancreatitis leads to nausea, vomiting and severe abdominal pain, which are the most common symptoms of this disease; it is highlighted that scorpionism itself can provoke such a picture (Carneiro & Siqueira-Batista, 2004; Sepúlveda et al., 2019). Organophosphate toxicity can manifest, clinically, in a similar way to injuries caused by scorpions; the distinction can be sought in terms of the possibility of exposure to such compounds (Vinhai & Soares, 2018).

Treatment

The first conduct of action to be taken after the scorpion bite is to wash the area with soap and water. Then, the victim must seek or be taken immediately to the health service for the assessment and observation of symptoms (Brasil, 2009). Most accidents with scorpions fall under mild cases, so treatment will depend on the clinical manifestations observed in the patient. It is worth mentioning that it is harmful and contraindicated to use a tourniquet, apply heat, squeeze, cut or place any substance on the wound site (Brasil, 2016). Medical management in mild to moderate cases involves the use of symptomatic drugs for local pain relief, the use of analgesics, such as dipyrone or meperidine, depending on the intensity of the pain, orally or parenterally, associated with local blockage by infiltration with 2% lidocaine without vasoconstrictor (Ciruffo, 2012). In moderate to severe cases, the stay in the hospital can vary from hours to days of hospitalization, requiring the administration of other medications such as metoclopramide, venous fluid therapy and correction of hydroelectrolytic, acid-base disorders and systemic arterial hypertension (Campos et al., 2020). It is also important to maintain electrocardiographic monitoring in the first 24 hours after admission (Cupo et al., 2003; Cupo, 2017).

Isolated signs and symptoms such as sweating, nausea, tachycardia, vomiting and tachypnea may occur in moderate cases. In severe cases, a drastic worsening of the clinical picture may occur, with emphasis on the occurrence of incoercible vomiting, dehydration, intense sweating, drooling, periods of prostration – alternating with agitation –, shock, heart failure, acute lung edema and coma (Cupo et al., 2003; Ciruffo et al., 2012; Carmo et al., 2019). The administration of anti-scorpion serum (SAE), intravenously, is reserved for such contexts. It's possible to acquire more information and to obtain the anti-scorpion serum by phone and emailing to Butantan, the information are available below: Customer Service (SAC): +55 0800 701 2850 e-mail: sac@butantan.gov.br (Table 1).

The serum that is supplied to the municipalities is only available in hospitals linked to the Unified Health System - in portuguese Sistema Único de Saúde (SUS) (Brasil, 2019). In health facilities where the SAE is missing, antiaracnicidic serum (ARS) may be used.

Table 1. Number of ampoules of antiscorpionic or antiaracnicidic serum (*Loxosceles*, *Phoneutria*, *Tityus*) specific according to the severity of the accident.

Antivenoms	Gravity	Nº of ampoules
SAEsc* ou SAA**	<i>Mild</i> : local pain and paresthesia ***	–
	<i>Moderate</i> : severe local pain associated with one or more manifestations (nausea, vomiting, sweating, sialorrhea, psychomotor agitation, tachypnea and tachycardia).	2 to 3
	<i>Severe</i> : in addition to the clinical manifestations mentioned in the moderate form, there is the presence of one or more of the following manifestations: profuse and incoercible vomiting, deep sweating, intense sialorrhea, prostration, convulsion, coma, bradycardia, heart failure, acute pulmonary edema and shock.	4 to 6

*SAEsc: antiscorpionic serum;

**SAA: antiaracnicidic serum (*Loxosceles*, *Phoneutria*, *Tityus*);

***Observation time of children bitten: 6 to 12 hours.

Source: adapted from Health Surveillance Guide, 2019.

Ecology and epidemiology of scorpionism

Scorpion species are present in almost all terrestrial ecosystems, with the exception of tundra, high latitude taiga, boreal areas and in some high altitude areas (Polis, 1990; Brasil & Porto, 2010). Most species have specific habitat conditions and presumed and localized in ecological and biogeographic patterns (Lourenço & Eickstedt, 2009).

These animals generally have nocturnal habits. They can be found in rocks' openings, trees' barks, decaying trunks, under rocks and leaves, and inside burrows and caves, protecting themselves from their natural predators (Soto-Blanco & Melo, 2018). In these places, temperature, humidity and the number of prey are decisive requirements for the installation and increase in the number of scorpions. In tropical regions, they are more frequent in periods with higher temperatures, especially when it rains. Scorpions are sitting-predators, and to catch prey, use sensory structures. If the prey is reluctant, the scorpion uses the venom to immobilize it and begins the digestion process. Despite pricking the prey, in some cases, scorpions do not inoculate the venom. In urban areas, these venomous animals can be good predators of arthropods, which are sometimes harmful to humans, such as insects and spiders (Brasil, 2009).

In Brazil, between 2007 and 2018, 1,899,795 accidents by venomous animals were reported in the Notifiable Diseases Information System (SINAN), of which 2,972 evolved to death (Figure 3A). Among accidents with venomous animals, the scorpion accident presented the greatest increase in the number of cases, from 37,368 notifications in 2007 to 155,859

in 2018, (Brasil, 2019) demonstrating that it was the accident with venomous animals with the highest incidence: 75.2 per 100,000 inhabitants. In this period, from 2007 to 2018, there were 927,750 cases and 972 deaths (Figure 3B).

The most occurrences of accidents with scorpions occurs among males, aged from 20 to 39 years. Women and children may present a more severe clinical condition, as they usually have lower body weight. In Brazil, most events are light; however, the severity of accidents depends on some factors, such as: species and quantity of inoculated venom and age of the victim (Brasil, 2016).

Prophylaxis and control

Prophylaxis and the control of scorpionism – in the world and in Brazil – are extremely important to avoid serious dislocations. For this reason, the dissemination of information – including the scorpion's ways of life – is extremely useful for the population to act in the control of accidents. It is always necessary to pay attention to clothes, shoes, bath / face towels and carpets by shaking them before use. Keep beds and cribs distanced from walls and floor, avoid accumulating debris and leave gardens without maintenance (Teixeira et al., 2017). When practicing services for handling construction materials, wood, gardens and others, it is always necessary to use Personal Protective Equipment (PPE) such as gloves and boots. Surveillance for control needs continuity and commitment, since scorpions are able to survive in adverse conditions for prolonged periods including climatic variations, even insecticides harmful to it (Brasil, 2016). It is of great importance that these prophylaxis and control measures are applied both in rural and urban areas (Brasil, 2016; Brasil, 2009).

Final considerations

Accidents involving scorpions should deserve attention from health professionals, considering the variety of existing species – with significant capacity to adapt to the environment –, the annual number of occurrences and the pathophysiological actions of venom related to *Homo sapiens*. This article addresses scorpion accidents, common events in Brazil, focusing on clinic, diagnosis and treatment, with a main focus on presenting up-to-date information on the conduct of these morbid conditions.

In addition, it should be noted that the subject is often little discussed in health courses, reflecting on an often unsafe service by health professionals. The information covered in this study will allow a broad understanding of scorpionism, in its various aspects epidemiological, physiological, diagnostic and therapeutic promoting the discussion on the topic and enabling the establishment of a safe and scientifically based service.

Acknowledgments

The authors are grateful to Professor Marcela Aparecida Toledo Milagres Duarte (FADIP) for the review of the English Language.

Ethical disclosures

Protection of human and animal subjects. This research was approved by the Institutional Review Board.

Right to privacy and informed consent. The authors declare that no data that enables identification of patients appears in this article.

Funding. This work was supported by authors

Conflict of interest. None declared

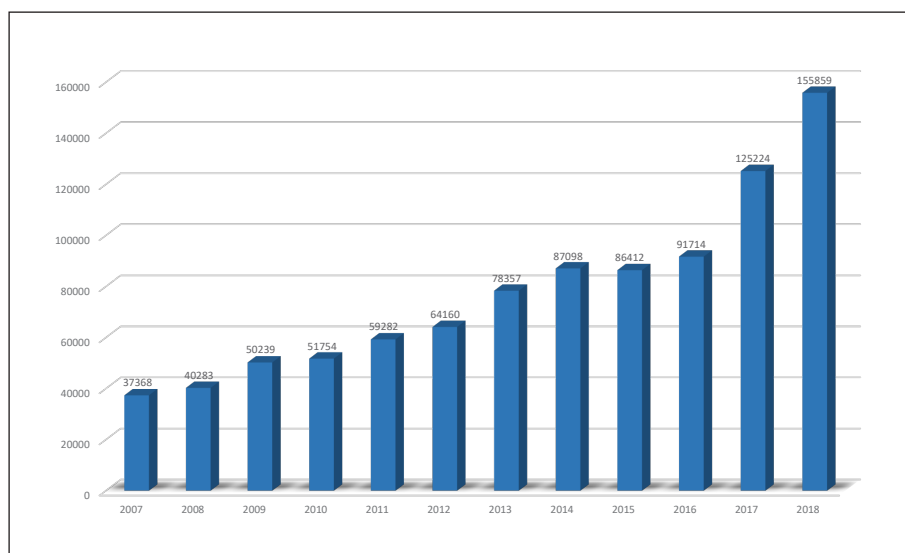


Figure 3A. Number of cases due to envenomings by scorpions in Brazil.

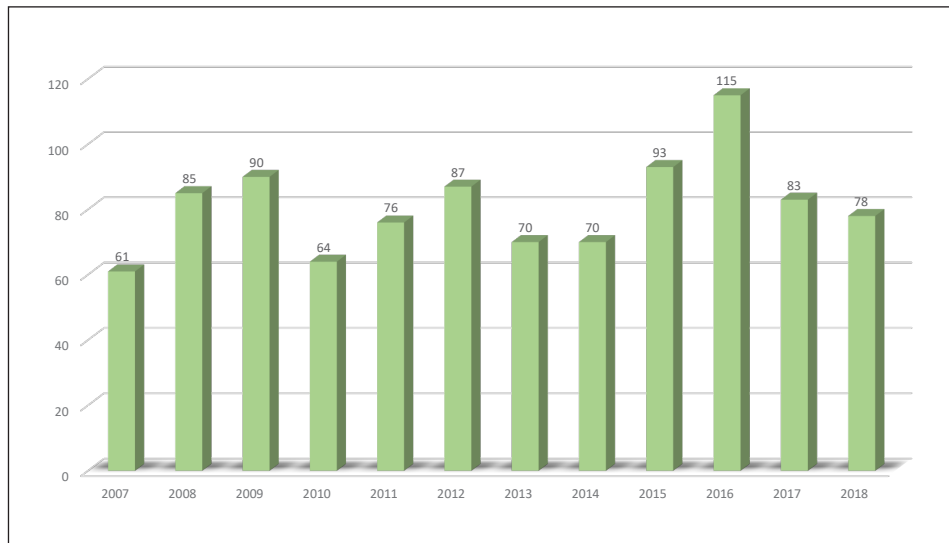


Figure 3B. Number of deaths due to envenomings by scorpions in Brazil.

References

- Abourazzak S, Achour S, El Arqam L, Atmani S, Chaouki S, Semlali I, Soulaymani Bencheikh R, Bouharrou A, Hida M. Epidemiological and clinical characteristics of scorpion. *J Venom Anim Toxins Incl Trop Dis*. 2009; 15(2): 255-267.
- Abroug F, Ouanes-Besbes L, Tilouche N, Elatrous S. Scorpion envenomation: state of the art. *Intens Care Med* 2020; 46:401-410.
- Albuquerque PLMM, Magalhães KDN, Sales TC, Paiva JHHGL, Daher EF, Silva Junior GBD. Acute kidney injury and pancreatitis due to scorpion sting: case report and literature review. *Rev Inst Med Trop Sao Paulo*. 2018; 60: e30.
- Almaaytah A, Albalas Q. Scorpion venom peptides with no disulfide bridges: a review. *Peptides* 2014; 51:35-45
- Amaral CFS, Lopes JA, Magalhães RA et al. Electrocardiographic, enzymatic and echocardiographic evidence of myocardial damage after *Tityus serrulatus* scorpion poisoning. *Am J Cardiol*. 1991; 67(7):655-7.
- Baldini AF, Cupo P, Pintya AO et al. Assessment of myocardial perfusion and function in victims of scorpion envenomation using gated-SPECT. *Arq Bras Cardiol*. 2010; 94(4):418-25.
- Barish R, Arnold T. Picadas de insetos. In: *Picadas de insetos*. [S. l.], agosto 2018. Disponível em: https://www.msmanuals.com/pt-pt/profissional/les%C3%B5es-intoxicac%C3%A7%C3%A3o/mordidas-e-picadas/picadas-de-insetos#v1117105_pt. Acesso em: 10 set. 2020.
- Barreira R, Magaldi RB. Distonia aguda após uso de bromoprida em pacientes pediátricos. *Rev Paul Pediatr* 2009; 27: 110-114.
- Batista EL. Por que os escorpiões agora preocupam – Saúde pública. Pesquisa Fapesp 247, setembro de 2016. Disponível em: https://revistapesquisa.fapesp.br/wp-content/uploads/2016/09/046-049_Escorpio-247.pdf. Acesso em: 07/11/2020
- Bernardes-Oliveira E, Farias KJS, Gomes DL, Araújo JMG, Silva WD, Rocha HAO, Donadi EA, Fernandes-Pedrosa MF, Crispim JCO. *Tityus serrulatus*. Scorpion Venom Induces Apoptosis in Cervical Cancer Cell Lines. *Evid-Based Complementary Altern Med* 2019; 5131042.
- Bizarro MB, Oliveira MA, Nery L, Alves DI. Miastenia gravis, o diagnóstico no olhar: relato de um caso. *Rev Port Med Geral Fam*, 2017; 33(6): 402-406.
- Branco ACSC, Maior FNS, Ramalho LSN, Gorgonio IF, Ramalho JA, Vinagre JBF, Diniz, MFFM. Atualizações e perspectivas na miastenia gravis. *Rev Bras Cien Saúde* 2011; 15(4), 493-506.
- Brasil. FUNASA. Manual de Diagnóstico e Tratamento de Acidentes por animais peçonhentos: acidentes por animais peçonhentos. 2ª ed. Brasília: Fundação Nacional de Saúde. 2001.
- Brasil. Ministério da Saúde, Secretaria de Vigilância em Saúde, Departamento de Vigilância Epidemiológica. Manual de controle de escorpiões. Brasília: Ministério da Saúde; 2009.
- Brasil. Ministério da Saúde, Secretaria de Vigilância em Saúde. Guia de Vigilância em Saúde. Brasília: Ministério da Saúde; 2016.
- Brasil. Ministério da Saúde. Secretaria de Vigilância em Saúde. Coordenação-Geral de Desenvolvimento da Epidemiologia em Serviços. Guia de Vigilância em Saúde: volume único [recurso eletrônico] / Ministério da Saúde, Secretaria de Vigilância em Saúde, Coordenação-Geral de Desenvolvimento da Epidemiologia em Serviços. – 3ª. ed. – Brasília: Ministério da Saúde, 2019.
- Brasil. Ministério da Saúde. Secretaria de Vigilância em Saúde. Departamento de Vigilância Epidemiológica. Doenças infecciosas e parasitárias: guia de bolso / Ministério da Saúde, Secretaria de Vigilância em Saúde, Departamento de Vigilância Epidemiológica. – 8. ed. rev. – Brasília: Ministério da Saúde, 2010.
- Bravo F, Calor A. Artrópodes do Semiárido: Biodiversidade e conservação. Feira de Santana: Printmídia, 2014.
- Brazil TK e Porto TJ. Os Escorpiões. Salvador: EDUFBA; 2010.
- Brites-Neto J. Aspectos Clínicos e Terapêuticos do envenenamento por escorpiões em cães e gatos. *Rev Cien Vet Saúde Pub* 2019; 6: 442-471.
- Cidade de São Paulo. Escorpiões. Disponível em: https://www.prefeitura.sp.gov.br/cidade/secretarias/saude/vigilancia_em_saude/controle_de_zoonoses/animais_sinantropicos/index.php?p=4504#:~:text=Alguns%20escorpi%C3%B5es%20reproduzem-se%20assexuadamente,as%20quais%20geram%20novas%20f%C3%AAsmeas. Acesso em: 7 out. 2020.
- Carneiro MC, Siqueira-Batista R. O mosaico patogênico da pancreatite aguda grave. *Rev Col Bras Cir* 2004; 31(6): 391-397, 2004.
- Campos, LL, Cardoso FL, Filho AA. Fisiopatologia e tratamento dos efeitos cardiovasculares e pulmonares no envenenamento por escorpião. *Rev. Med Minas Gerais* 2020; 30: e-30203.
- Carmo ÉA, Nery AA, Pereira R, Rios MA, Casotti CA. Fatores associados à gravidade do envenenamento por escorpiões. Texto contexto - Enferm [Internet]. 2019;28: e20170561.
- Carmo, Bruno Amorim do. Caracterização estrutural e potencial antimicrobiano, antiparasitário e antiproliferativo de novos peptídeos análogos da stigmurina. 2019. 99f. Dissertação (Mestrado em Ciências Farmacêuticas) - Centro de Ciências da Saúde, Universidade Federal do Rio Grande do Norte, Natal, 2019.
- Carvalho LS, Brescovit AD, Souza CAR, RaizerJ. Checklist dos escorpiões (Arachnida: Scorpiones) do Mato Grosso do Sul, Brasil. *Iheringia. Série Zoologia (Online)* 2017; 107:1-7.
- Chávez-Olórtegui C, Kalapothakis E. Selected to survive and kill: *Tityus serrulatus*, the Brazilian yellow scorpion. *PLoS One*. 2019;14(4):e0214075.
- Cruffo PD, Coutinho LO, Boroni JD, Diniz AET, Diniz WF. Escorpionismo: quadro clínico e manejo dos pacientes graves. *Rev Med Minas Gerais* 2012;22(Supl 8):S1-S48
- Coelho JS, Ishikawa EAY, Santos PRSG, Pardo PPO. Spionism by *Tityus silvestris* in eastern Brazilian Amazon. *J Venom Anim Toxins Trop Dis* 2016; 22: 24.
- Cupo P, Azevedo-Marques MM, Hering SE. Acidentes por animais peçonhentos: escorpiões e aranhas. *Urgências e Emergências Dermatológicas e Toxicológicas, Medicina Ribeirão Preto*. 2003; 36:490-7.

31. Cupo, P. Acidente escorpiônico na Sala de Urgência. *Rev Qualidade HC* 2017; 1:1-3.
32. Elatrous S, Nouira S, Besbes-Ouanes L et al. Dobutamine in severe scorpion envenomation. *Chest*. 1999; 116(3):748-53.
33. Dias NB. Estudo peptídico e determinação do perfil de metabólitos de escorpiões da família Buthidae: *Tityus serrulatus*, *Tityus bahiensis* e *Tityus obscurus*. Rio Claro: UNESP, 2016.
34. França FOS, Medeiros CR, Zannin M, Wen FH, Málauque CMS, Cardoso JLC. Acidentes por aracnídeos e insetos. In: Veronesi R, Focaccia R. *Tratado de Infectologia*. 5. ed. rev. e atual. São Paulo: Atheneu, 2015.
35. Franco, Stanley Philippe Antunes et al. Accidents caused by *Lonomia*, in Minas Gerais, 2001 a 2006. *Rev Med Minas Gerais* 2020; 30: 1-8.
36. Furtado AA, Silva AD, Júnior AAS, Pedrosa MFF. Biology, venom composition, and scorpionism induced by brazilian scorpion *Tityus stigmurus* (Thorell, 1876) (Scorpiones: Buthidae): A mini-review. *Toxicon*;185:36-45, 2020.
37. Galvani NC. Avaliação genômica e dopaminérgica do tratamento com soro antiescorpiônico em animais inoculados com veneno do escorpião *Tityus serrulatus* Lutz & Mello, 1922, 2019.
38. Geron M, Margulis G, Ilia R et al. The management of scorpion envenomation 1993 [letter]. *Toxicon* 1993; 31(9):1071-83.
39. Gomes AP, Rita-Nunes E, Viana LEO, Pinto RCT, Pinto-Nunes NR, Porto-Da-Luz CRD, Pereira-Redondo S, Bittencourt-Costa JR, Mukamal RC, Esperidião-Antonio V, Silva Santos S. Botulismo: estudo clínico. *J Bras Med* 2008; 94: 44-47.
40. Graca FAS, Peixoto PV, Coelho CD, Caldas SA & Tokarnia CH. 2008. Aspectos clínico-patológicos e laboratoriais do envenenamento crotálico experimental em bovinos. *Pesq. Vet. Bras*. 28:261-270.
41. Hassan F. Production of scorpion antivenom. In: TU AT. Ed. *Handbook of Natural Toxins*. New York: Marcel Dekker, 1984.
42. Hering SE, Jurca M, Vichi F, Azevedo-Marques MM, Cupo P. Reversible cardiomyopathy in patients with severe scorpion envenoming by *Tityus serrulatus*: evolution of enzymatic, electrocardiographic and echocardiographic alterations. *Ann Trop Paediatr*. 1993; 13(2):173-82.
43. Ismail M, Abd-Elsalam MA. Are the toxicological effects of scorpion envenomation related to tissue venom concentration? *Toxicon* 1988; 26(3): 233-256.
44. Jared C, Mailho-Fontana PL, Antoniazzi MM. Differences between poison and venom: An attempt at an integrative biological approach. *Acta Zoologica*. 2021;00:1-14.
45. Karnad DR. Hemodynamic patterns in patients with scorpion envenomation. *Heart*. 1998; 79(5):485-9.
46. Kuiava VA, Nalin LV, Pazzini LV, Santana VB. Vigilância Epidemiológica de Ataques de Animais Peçonhentos notificados no Brasil. Atena Editora, 2019.
47. Lira AFA, Guilherme E, Souza MB, Carvalho LS. Scorpions (Arachnida, Scorpiones) from the state of Acre, southwestern Brazilian Amazon. *Acta Amazonica* 2021; 51: 58-62.
48. Lourenço WR, Eickstedt VR. Escorpiões de importância médica. In: Cardoso JLC et al. *Animais peçonhentos no Brasil: biologia, clínica e terapêutica dos acidentes*. São Paulo: Sarvier, 2009.
49. Lourenço WR. *Scorpions of Brazil*. Paris: Les Éditions l' if. 1st ed., 2002.
50. Martins KP, Garcia DA, Cortez AM, Gomes DE. Escorpionismo - Revisão de Literatura. *Rev Cient* 2018; 1(1): 1-8.
51. Machado RJA. Caracterização estrutural e avaliação da atividade biológica de uma nova hipotensiva identificada no veneno do escorpião *Tityus stigmurus*. 2016. 133f. Tese (Doutorado em Bioquímica) - Centro de Biociências, Universidade Federal do Rio Grande do Norte, Natal, 2016.
52. Ministério da Saúde. Tétano Acidental: o que é, causas, sintomas, tratamento, diagnóstico e prevenção. Disponível em: <https://saude.gov.br/saude-de-a-z/tetano-acidental>. Acesso em: 10 set. 2020.
53. Ministério da Saúde. Manual Integrado de Vigilância Epidemiológica do Botulismo: série a. normas e manuais técnicos. Brasília: Editora MS, 2006.
54. Moake, JL. Coagulação intravascular disseminada, julho 2019. Disponível em: https://www.msmanuals.com/pt/profissional/hematologia-e-oncologia/dist%C3%BArbios-de-coagula%C3%A7%C3%A3o/coagula%C3%A7%C3%A3o-intravascular-disseminada-cid#v972519_pt. Acesso em: 10 set. 2020.
55. Nencioni ALA, Neto EB, de Freitas LA, Dorce VAC. Effects of Brazilian scorpion venoms on the central nervous system. *J Venom Anim Toxins Incl Trop Dis* 2018; 24: 3.
56. Oguiura N. Venenos e toxinas: uma abordagem multidisciplinar. *Biológico* 2004; 66(1/2):57.
57. Ortiz E, Gurrola GB, Schwartz EF, Possani LD. 2015. Scorpion venom components as potential candidates for drug development. *Toxicon* 2015; 93: 125-135.
58. Paz GG, Oliveira MP, Miranda FS, Alves LV, Errante PR, Carvalho RG, Menezes-Rodrigues FS. Efeitos tóxicos causados por envenenamento escorpiônico no Brasil. *UNILUS Ensino e Pesquisa* 2020; 17(46): 92-99.
59. Polis GA. *The Biology of Scorpions*. Ed. Stanford University Press, Stanford, CA, 1990.
60. Pucca MB, Cerni FA, Pinheiro Junior EL, Bordon KCF, Amorim FG, Cordeiro FA, Longhim HT, Cremonez CM, Oliveira GH, Arantes EC. *Tityus serrulatus* venom – a lethal cocktail. *Toxicon* 2015; 108: 272-284.
61. Puerto G, Sant'anna SS, Grego KF, Antoniazzi MM, Jared C, Candido DD, Nanni PN, Moraes RHP, Guizze SPG, Fan HW, Malaque CMS. Animais venenosos: serpentes, anfíbios, aranhas, escorpiões, insetos e lacraias. 2.ed.rev.ampl. – São Paulo: Instituto Butantan, 2017.
62. Rahmani A, Jalali A. Symptom patterns in adult patients stung by scorpions with emphasis on coagulopathy and hemoglobinuria. *J Venom Anim Toxins Trop Dis* 2012; 18(1): 427-431.
63. Reckziegel GC. Análise do escorpionismo no Brasil no período de 2000 a 2010. 2013. 103 f., il. Dissertação (Mestrado em Saúde Coletiva). Universidade de Brasília, Brasília, 2013.
64. Reckziegel GC, Pinto VL. Scorpionism in Brazil in the years 2000 to 2012. *J Venom Anim Toxins Trop Dis* 2014; 20(1): 46.
65. Reis MB, Zoccal KF, Gardinassi LG, Faccioli LH. Scorpion envenomation and inflammation: Beyond neurotoxic effects. *Toxicon* 2019; 167: 174-179.
66. Rezende, N. A., Dias M. B., Campolina, D., et al. Standardization of an enzyme linked immunosorbent assay (ELISA) for detecting circulating toxic venom antigens in patients stung by the scorpion *Tityus serrulatus*. *Rev Inst Med Trop São Paulo* 1995; 37(1): 71-74.
67. Salvatierra L e Ramos WR. Brazilian wandering spider accident with sequela of Raynaud phenomenon. *Revista Pan-Amazônica de Saúde* 2018; 9(4): 1-1.
68. Santana LA, Souza HJ, Sant'Ana JLP, Rodrigues NM, Oliveira TT. Araneísmo. In: Siqueira-Batista R, Gomes AP, Santos SS, Santana LA. *Parasitologia: fundamentos e prática clínica*. Rio de Janeiro: Guanabara Koogan, 2020a. p. 621-624.
69. Santana LA, Vicari MV, Motta OJR, Novelli MM, Montenegro SSP, Pereira SO, Machado GR, Sant'Ana JLP, Silva E. Arachnidism in Brazil. *Braz J Health Rev* 2020b; 3(5):12859-12872.
70. SBMT. Acidentes com escorpiões: aumento expressivo preocupa autoridades e população. Sociedade Brasileira de Medicina Tropical. Publicação online abril, 2019. Disponível em: <https://www.sbmt.org.br/portal/acidentes-with-scorpions-significant-increase-worries-authorities-and-population/>. Acesso em 06/11/2020.
71. Sepulveda EVF & Guerrero-Lozano R. Acute pancreatitis and recurrent acute pancreatitis: an exploration of clinical and etiologic factors and outcomes. *J Ped* 2019; 95(6): 713-719.
72. Silva KRLM. Envenenamento pela taratuna *Lonomia obliqua*: estudo das propriedades hemorrágica e inflamatória do veneno em modelos animais. Porto Alegre. Universidade Federal do Rio Grande do Sul, 2007.
73. Silva NA, Albuquerque CMR, Marinho AD, Jorge RJB, Neto AGS, Monteiro HSA, Silva TD, Silva MV, Correia MTS, Pereira TP, Martins AMC, Menezes DB, Ximenes RM, Martins RD. Effects of *Tityus stigmurus* (Thorell 1876) (Scorpiones: Buthidae) venom in isolated perfused rat kidneys. *An Acad Bras Ciênc* 2016; 88(supl.1): 665-675.
74. Siqueira-Batista R, Albuquerque AKAC, Esperidião Antonio V, Gomes AP, Quintas LEM. O sistema nervoso autônomo. *Rev Bras Clín Terap* 2004; 30(5): 206-212.
75. Siqueira-Batista R, Albuquerque GLC, Feio RN, Silva Santos S. Ofidismo. In: Siqueira-Batista R, Gomes AP, Silva Santos S, Santana LA. *Parasitologia: fundamentos e prática clínica*. Rio de Janeiro: Guanabara Koogan, 2020
76. Soto-Blanco B Melo MM. Escorpionismo. *Cad Tec Saúde* 2019; 3:1.
77. Teixeira CSB, Mello LG, Correia KN, Freitas RC, Silva TLB, Soares MA. Práticas de educação ambiental na prevenção de acidentes com escorpiões na zona oeste do Rio de Janeiro – RJ. Sigabi - 6º Simpósio de Gestão Ambiental e Biodiversidade - UFRRJ, 2017.
78. Triches CMF. Predição e caracterização de um epitopo conformacional da beta-neurotoxina TSI do escorpião *Tityus serrulatus*. *Criciúma: UNESC*, 2017.
79. Weiss MB, Paiva JWS. Acidentes com Animais Peçonhentos. Rio de Janeiro: Revinter, 2018.
80. Zhijian C, Feng L, Yingliang W, Xin M, Wenxin L. Genetic mechanisms of scorpion venom peptide diversification. *Toxicon* 2006; 47: 348-355.